

# Visual Outcome and Complications of 23 G Versus 20 G Vitrectomy in Cases of Diabetic Vitreous Haemorrhage

Washoo Mal, Shakir Zafar, Zafar Iqbal, Syed Fawad Rizvi, Syed Asad Mahmood

*Pak J Ophthalmol 2014, Vol. 30 No. 3*

See end of article for authors affiliations

Correspondence to:

**Washoo Mal**

LRBT Free Base Eye hospital

Korangi 2 ½, Karachi

Postal code: 74900

E-mail: dr.wash\_72@yahoo.com

**Purpose:** To compare post-operative visual outcome and complications of 23-gauge versus 20-gauge pars plana vitrectomy in cases of vitreous haemorrhage secondary to proliferative diabetic retinopathy.

**Material and Methods:** Randomized clinical trial conducted at LRBT, Free Base Eye Hospital, Karachi, from January 2010 to June 2012. Two hundred sixty patients of vitreous haemorrhage secondary to proliferative diabetic retinopathy (Type – I diabetes mellitus) were randomly selected, age range between 30 – 70 years, 23 – gauge (n = 130) group A; males 73 (56.16%), females 57 (43.85%) and 20 – gauge pars plana vitrectomy (n = 130) group B; males 70 (53.85%), females 60 (46.15%). Post-operative follow up were at day one, 1 week, 1 month, 2 month, 3 month and final 6 month. Data was analyzed and compared for post-operative best corrected visual acuity (BCVA) and complications between two groups.

**Results:** Visual acuity significantly improved in majority of patients in both groups. In group A 65.38% (85 patients) achieved between 6/6 - 6/24 and in group B 63.85% (83 patients) in same range when measured finally at 6 month post-operative. Post operative complications in group A were transient hypotony 10.77% (14 eyes), recurrent vitreous haemorrhage 6.15% (8 eyes), raised IOP 3.08% (4 eyes), Cataract 3.84% (5 eyes), Itrogenic tear 9.23% (12 eyes), vitreous show (prolapsed) 3.84% (5 eyes) and 1 patient (0.76%) developed endophthalmitis which was treated successfully. While in group B transient hypotony 6.15% (8 eyes), recurrent vitreous haemorrhage 18.46% (24 eyes), raised IOP 7.69% (10 eyes), Cataract 3.84% (5 eyes), Itrogenic tear 7.69% (10 eyes) and phthisis bulbus 0.76% (1 eye), corneal edema 6.92% (9 eyes), and conjunctival granuloma at surgical wound 2.30% (3 eyes) observed.

**Conclusion:** 23 – gauge micro-incision Vitrectomy system MIVS and 20-gauge pars plana vitrectomy showed improvement in best corrected visual acuity (BCVA) while early visual recovery and less complications rate seen in patients of 23 – gauge group.

**Key words:** Vitrectomy, Diabetic retinopathy, Vitreous haemorrhage.

It has been estimated that 8.5 – 12% population Pakistan suffering from diabetes mellitus, type-II is more common and prevalence of proliferative diabetic retinopathy 2.65 – 5% in our country.<sup>1,2</sup> Vitreous haemorrhage due to proliferative diabetic retinopathy (PDR) is one of major cause of visual

impairment and due to emergence of vitrectomy system and rapid advancement in surgical techniques for posterior segment pathologies led to improvement in visual outcome after surgery.

Pars plana vitrectomy (PPV) is one of the most commonly performed surgical procedure for

treatment of various vitreo-retinal diseases. Machemer et al introduced PPV in 1971<sup>3</sup>. More than Last 30 years, the 3-port 20-gauge PPV remained the standard vitreo-retinal surgery<sup>4</sup>. Pars plana vitrectomy involves conjunctival incision, sclerotomies and suturing but now-a-day's 20-gauge PPV is also performed transconjunctivally to make entry wound through the conjunctiva and sclera together, which does not required conventional suturing. These sutureless self sealing sclerotomies for PPV were first designed by Chen in 1996<sup>5</sup>.

In 2002, Fujii et al introduced the 25-gauge transconjunctival sutureless micro-incision vitrectomy surgery (MIVS).<sup>6,7</sup> After few years, in 2005 Eckardt developed the 23-gauge transconjunctival vitrectomy system<sup>8</sup>. Though the advances in surgical equipments and techniques, the vitrectomy procedure requires a skilled and experienced surgeon. Conventional 3-port 20-gauge PPV need 1.2 mm wide sclerotomies, performed after conjunctival peritomy and surgical wound secured with sutures that may cause subconjunctival haemorrhage, congestion and foreign body sensation responsible for post-operative discomfort as well as prolong surgical time<sup>9</sup>. In recent years, the 23-gauge transconjunctival sutureless vitrectomy (TSV) has become the preferred MIVS system of vitreo-retinal surgeons because of its smaller sclerotomies of 0.72 mm width and leads decrease surgical trauma, minimum post-operative inflammation, faster healing and due to its sutureless, shortens the surgical time.<sup>10-12</sup> The 23-gauge vitrectomy system has advantage to overcome the excessive flexibility of instruments used in smaller diameter 25-gauge MIVS, which may cause hindrance in maneuvering the globe during surgery<sup>13</sup>.

The rationale of this study is to compare post-operative visual outcome and complications between 23-gauge MIVS and 20-gauge pars plana Vitrectomy.

## MATERIAL AND METHODS

In this prospective, randomized clinical trial of 260 patients of vitreous haemorrhage secondary to proliferative diabetic retinopathy (Fig. 1) were randomly selected for 23 - gauge MIVS (n = 130) and 20 - gauge PPV (n = 130) for indication of diabetic vitreous haemorrhage during period of January, 2010 to June, 2012, carried out in LRBT, Free Base Eye Hospital, Karachi. All surgeries were carried out by one vitreo-retinal surgeon (SZ). The data acquisition was performed by two investigators (ZI) independently of

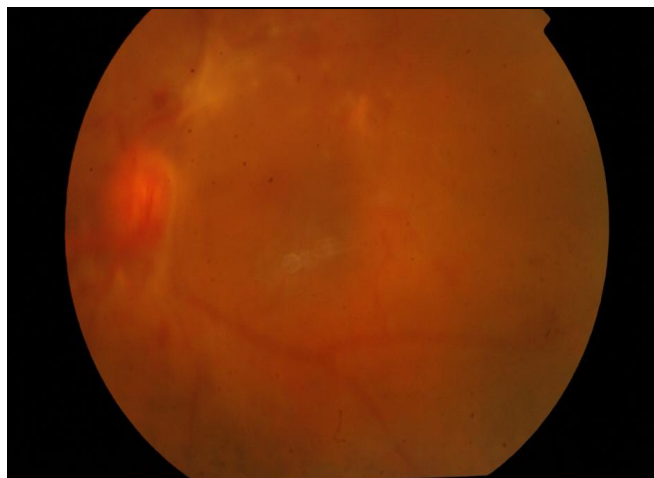
surgeon, while literature was reviewed by doctor (WM). The study was conducted under the supervision of hospital incharge (SFR). The study was approved by institutional ethical review committee, and informed consent was taken from each patient.

Cases of diabetic vitreous haemorrhage secondary to type - II diabetes mellitus, without significant cataract and patients with pseudophakia were included in this study while patients associated with advanced or complicated PDR like retinal detachment, proliferative vitreo-retinopathy, uveitis, dense cataract and previous history of vitreo-retinal surgery were excluded from study and in invisible fundi dynamic B-scan ultrasound carried out to rule out retinal detachment or any significant fibrotic bands. Pre-operative ocular & systemic examination of all patients done, including: visual acuity (Snellen's Chart), ocular adnexa, anterior segment examination, intra ocular pressure, crystalline lens for opacities (cataract) and dilated fundal examination with +90 D lens at bio-microscopic slit lamp, indirect ophthalmoscopy, blood pressure, fasting blood sugar and HbA1c were checked. All patients were informed about the procedure and written consent taken. Surgeries were performed by using vitrectomy system) and non-contact viewing system (EBIOS) for visualization and illumination provided by Xenon light.

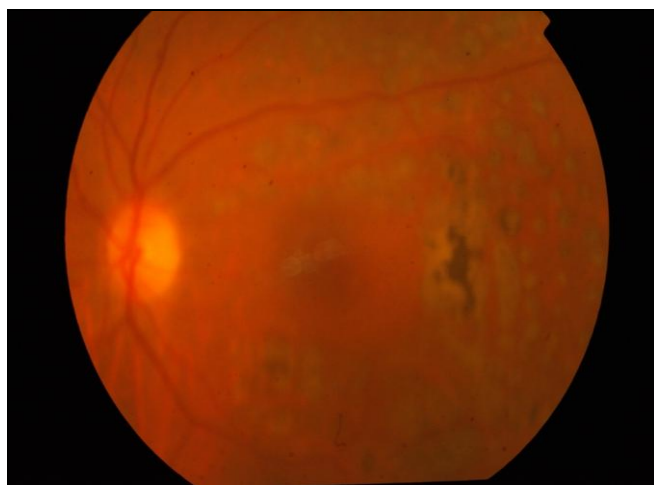
The rationale of this study is to compare post-operative visual outcome and complications between 23-gauge MIVS and 20-gauge pars plana vitrectomy.

## Surgical Technique

All surgeries done under local anaesthesia preferably retrobulbar with 2 ml of lidocain 2% and 2 ml of bupivacain 0.75% were used. All surgeries were carried out under strict aseptic measures using povidone iodine 5-10% for periocular paint and conjunctival fornices with 5% same solution. After applying eye speculum, self-retaining trocar/cannulae inserted transconjunctivally after 1.5-2 mm displacing conjunctiva laterally at supero-temporal, supero-nasal and infero-temporally about 3.5 mm away from the limbus, 30° obliquely to have sclera tunnel in all phakic patients. The infusion line was connected to infero-temporal cannula while superior two cannulae for illumination and vitrectomy cutter, after complete vitreous cleaning, the retina was examined and pan retinal photocoagulation was done using endolaser (Fig: 2). Balance salt solution was used as internal tamponade. At the completion of vitrectomy the



**Fig. 1:** Pre operative Fundus photograph of Vitreous Haemorrhage



**Fig. 2:** Fundus photograph after Pars Plana Vitrectomy with Endolaser

superior cannulae were plugged and infusion line was stopped. Initially superior cannulae were removed with observing the repositioning of conjunctiva covering the sclerotomies finally infero-temporal cannula with infusion line removed and observed repositioning of conjunctiva; finally the sclerotomies in group A, of 23-gauge MIVS left sutureless. (No any patient required suturing in group A) In Group B, 20-gauge sclerotomies were done with MVR blade and infero-temporally infusion canula was sutured with vicryl 6/0. At end of surgery, the sclerotomies and conjunctiva were sutured with vicryl 6/0 (Ethicon, Johnson and Johnson).

The data was collected for variables like, age, gender, best corrected visual acuity (BCVA). Pre-

operatively and post-operatively follow up were at day one, 1 week, 1 month, 2 month, 3 month and finally at the end of 6 months visual acuity measured with Snellen's chart followed by refraction (where needed) and various post-operative complications were evaluated. Variables were statistically analyzed by Wilcoxon test for pre & post operative BCVA and Chi-square's Test and Fisher's Exact Test where applied for comparison two groups. A P-value  $\leq 0.05$  considered statistically significant.

## RESULTS

Data of two hundred sixty eyes of 260 patients were analyzed, 130 in each group A for 23-gauge MIVS and group B for 20-gauge PPV. Age range was 30 to 70 years, 73 (56.15%) males and 57 (43.85%) females in group A while 70 (53.85%) males and 60 (46.15%) females in group B. BCVA of two groups were analysed by applying Wilcoxon test (NPar) to compare pre and post BCVA of two groups, that showed significant improvement (p-value 0.0001).

BCVA differences in patients of two groups were insignificant when measured finally at 6 months post-operatively shown in Table 1. In group A 85 (65.38%) improved between 6/6 - 6/24, 6/36 24 (18.46%), 6/60 11 (8.46%), CF 6 (4.61%), HM 4 (3.10%); whereas group B improved 83 (63.85%) - 6/6 - 6/24, 22 (16.92%) - 6/36, 13 (10%) - 6/60, 7 (5.38%) - CF, 5 (3.85%) -HM (HM due to ischemic neuropathy proven by FFA and recurrent vitreous haem.). P-value of BCVA between two groups remained insignificant. Early visual recovery observed in group A that might be due to lesser manipulation. Post-operative complications are summarized the table 2. Only one patient (0.76%) in group A developed endophthalmitis which was successfully treated with standard intra-vitreous, topical and systemic antibiotics and one eye (0.76%) in group B end up into phthisis bulbus. In spite of itrogenic tears, no any patient developed retinal detachment. Because confluent lasers were applied around tears.

## DISCUSSION

In this study post operatively BCVA of both groups at 6 months significantly improved shown in (table 1) from hand movement to between 6/6 to 6/24 in 65.38% (85/130 patients) in 23-gauge group and 63.85% (83/130 patients) in 20-gauge group; which shows insignificant statistical difference between two groups. A study of Kim JM et al shows BCVA 6/6 to 6/24 in 72.72% in cases of vitreous haemorrhage 23-

**Table 1:** Comparison only for Post BCVA (Group A and Group B), N = 260

BCVA	Group A (n = 130)		Group B (n = 130)		P-value b/w Two Groups
	Pre-op (%)	Post-op At 6 Month (%)	Pre-op (%)	Post-op At 6 Month (%)	
6/6 - 6/24	-	85 (65.38)	-	83 (63.85)	0.79
6/36	9 (6.92)	24 (18.46)	8 (6.15)	22 (16.92)	0.74
6/60	21 (16.15)	11 (8.46)	23 (17.69)	13 (10)	0.66
CF	46 (35.38)	6 (4.61)	48 (36.92)	7 (5.38)	0.77
HM	54 (41.35)	4 (3.10)	51 (39.23)	5 (3.85)	1.00

**Table 2:** Post-operative Complications, N = 260

Disease	Group A (n = 130)	Group B (n = 130)
	No. of Eyes n (%)	No. of Eyes n (%)
Transient hypotony	14 (10.77)	08 (6.15)
Recurrent vitreous haemorrhage	8 (6.15)	24 (18.46)
Raised IOP $\geq$ 30 mmHg	4 (4.08)	10 (7.69)
Cataract	5 (3.84)	5 (3.84)
Iatrogenic retinal tears	12 (9.23)	10 (7.69)
Endophthalmitis	01 (0.76)	00 (0.0)
Phthisis bulbus	00 (0.0)	01 (0.76)
Vitreous show (prolapsed)	- (-)	05 (3.84)
Conjunctival granuloma at wound	- (-)	03 (2.30)
Corneal oedema	- (-)	06 (6.92)

gauge vitrectomy which is much better improvement than this study<sup>14</sup>. This difference in visual outcome is due to variation in case selection. Nataraj AMS mentioned significant BCVA improvement in his study of 23-gauge and 20-gauge technique with insignificant statistical difference in two groups, which is comparable to this study<sup>15</sup>.

Complications summarized in table 2, showing hypotony (defined as  $\leq$  5 mm Hg intraocular pressure)<sup>16</sup> occurred in 10.77% (14/130 eyes) in 23-gauge and 6.15% (8/130 eyes) in 20 - gauge groups which was normalized in 2 weeks with use of topical steroids and cycloplegics. Woo SJ et al noted post-operative hypotony in 11.3% in 23-gauge vitrectomy<sup>17</sup> and these results are comparable to this study. Related

to this multiple studies and literature shows increase incidence of post-operative hypotony in sutureless vitrectomy.<sup>6,11,18</sup> Intraocular pressure  $\geq$  30 mm Hg was observed in 3.08% (4/130 eyes) in 23-gauge and 7.69% (10/130 eyes) in 20 - gauge groups. This would be due to suturing of sclerotomies in respective groups. Misra A et al mentioned raise IOP 8% (4/50 eyes) in 20-gauge vitrectomy, that incidence is matched to this study. Iatrogenic retinal breaks in 23-gauge and 20-gauge groups are 10.77% (14/130 eyes) and 9.23% (12/130 eyes) respectively. Misra A et al also shows iatrogenic breaks 14% and 12% in 23 - gauge and 20 - gauge respectively which is higher than this study<sup>19</sup>.

As the 23-gauge vitrectomy is sutureless nature of surgery is vulnerable to most serious complication -

the endophthalmitis, Kunimoto et al in one large retrospective case series has shows incidence of endophthalmitis after sutureless 25 gauge (MIVS) is 12 times higher than conventional 20-gauge vitrectomy<sup>20</sup>. However in subsequent case series of Hu AY et al and Parolini B et al have shows no increase incidence of endophthalmitis in 25 - gauge and 23-gauge compared with 20-gauge vitrectomy<sup>21,22</sup>. In this study single case developed endophthalmitis, this was successfully treated with intravitreal, topical and systemic antibiotics. The cause of post surgical endophthalmitis might have involved factors other than sutureless vitrectomy. Misra A et al and Romano MR mentioned in their studies that sutureless vitrectomy theoretically may be at greater risk of this dangerous complication.<sup>19,23</sup>

Recurrent vitreous hemorrhage noticed in 8% (21 cases in both groups) more probably due to underlying basic pathology of proliferative diabetic retinopathy.

## CONCLUSION

This study concludes that 23 - gauge MIVS and 20 - gauge pars plana vitrectomy showed improvement in best corrected visual acuity (BCVA), while low rate of complications seen in 23 - gauge MIVS except hypotony is higher due to sutureless surgery and preferably MIVS should be considered first choice where ever possible.

## Author's Affiliation

Dr. Washoo Mal  
Associate Ophthalmologist  
LRBT Free Base Eye Hospital  
Korangi 2 ½, Karachi  
Postal code: 74900

Dr. Shakir Zafar  
Consultant Ophthalmologist  
LRBT Free Base Eye Hospital  
Korangi 2 ½, Karachi  
Postal code: 74900

Dr. Zafar Iqbal  
Consultant Ophthalmologist  
LRBT Free Base Eye hospital  
Korangi 2 ½, Karachi  
Postal code: 74900

Dr. Syed Fawad Rizvi  
Chief Consultant Ophthalmologist  
LRBT Free Base Eye Hospital  
Korangi 2 ½, Karachi  
Postal code: 74900

Dr. Syed Asad Mahmood  
Resident medical officer  
LRBT Free Base Eye hospital  
Korangi 2 ½, Karachi  
Postal code: 74900

## REFERENCES

1. **Memon WU, Jadoon Z, Qidwai U, Naz S, Dawar S, Hasan T.** Prevalence of diabetic retinopathy in patients of age group 30 years and above attending multicentre diabetic clinics in Karachi. *Pak J Ophthalmol.* 2012; 28: 99-104.
2. **Hussain F, Arif M, Ahmad M.** The prevalence of diabetic retinopathy in Faisalabad, Pakistan: a population-based study. *Turk J Med Sci.* 2011; 41: 735-42.
3. **Machemer R, Buettner H, Norton EW, Parel JM.** Vitrectomy: a pars plana approach. *Trans Am Acad Ophthalmol Otolaryngol.* 1971; 75: 813-20.
4. **O'Malley C, Heintz RM Sr.** Vitrectomy with an alternative instrument system. *Ann Ophthalmol.* 1975; 7: 585-8.
5. **Chen JC.** Sutureless pars plana vitrectomy through self-sealing sclerotomies. *Arch Ophthalmol.* 1996; 114: 1273-5.
6. **Fujii GY, De Juan E Jr, Humayun MS, Pieramici DJ, Chang TS, Awh C, Ng E, Barnes A, Wu SL, Somerville DN.** A new 25-gauge instrument system for transconjunctival sutureless vitrectomy surgery. *Ophthalmology.* 2002; 109: 1814-20.
7. **Fujii GY, De Juan E Jr, Humayun MS, Chang TS, Pieramici DJ, Barnes A, Kent D.** Initial experience using the transconjunctival sutureless vitrectomy system for vitreoretinal surgery. *Ophthalmology.* 2002; 109: 1814-20.
8. **Eckardt C.** Transconjunctival sutureless 23-gauge vitrectomy. *Retina.* 2005; 25: 208-11.
9. **Jackson T.** Modified sutureless sclerotomies in pars plana vitrectomy. *Am J Ophthalmol.* 2000; 129: 116-7.
10. **Meyer CH, Rodrigues EB, Schmidt JC, Horle S, Kroll P.** Sutureless vitrectomy surgery. *Ophthalmology.* 2003; 110: 2427-8.
11. **Soni M, ChHugh D.** 23-Gauge transconjunctival sutureless vitrectomy: a way forward. *Eye News.* 2007; 14: 18-20.
12. **Lakhanpal RR, Humayun MS, De Juan E Jr, Lim JI, Chong LP, Chang TS, Javaheri M, Fujii GY, Barnes AC, Alexandrou TJ.** Outcomes of 140 consecutive cases of 25-gauge transconjunctival surgery for posterior segment disease. *Ophthalmology.* 2005; 112: 817-24.
13. **Nam Y, Chung H, Lee JY, Kim JG, Yoon YH.** Comparison of 25 and 23-gauge sutureless microneuronal vitrectomy surgery in the treatment of various vitreoretinal diseases. *Eye* 2010; 24: 869-74.
14. **Kim JM, Park HK, Hwang MJ, Yu GH, Suk Y, Yu, Chung H.** The safety and efficacy of transconjunctival sutureless 23-gauge vitrectomy. *Korean Journal of Ophthalmology.* 2007; 21: 201-7.
15. **Nataraj AMS.** Comparison Between 20 - gauge and 23-gauge Vitrectomy In Diabetic Patients. *Kerala Journal of Ophthalmology.* 2011; 23: 293-7.
16. **Kanski JJ, Bowling B.** editors. Acquired macular disorders. In: *Clinical ophthalmology a systemic approach.* Edinburg: Elsevier; 2011; 594-646.
17. **Woo Sj, Park KH, Hwang JM, Kim JH, Yu YS, Chung H.** Risk factors associated with sclerotomy leakage and postoperative hypotony after 23-gauge transconjunctival sutureless vitrectomy. *Retina.* 2009; 29: 456-63.
18. **Fine HF, Iranmanesh R, Iturralde D, Spaide RF.** Outcomes of 77 consecutive cases of 23-gauge transconjunctival vitrectomy

- surgery for posterior segment disease. *Ophthalmology*. 2007; 114: 1197-1200.
19. **Misra A, Ho-Yen G; Burton RL.** 23-gauge Sutureless Vitrectomy and 20-gauge Vitrectomy: A Case Series Comparison. *Eye*. 2009; 23:1187-91.
  20. **Kunimoto DY, Kaiser RS.** Wills Eye Retina Service. Incidence of endophthalmitis after 20 and 25-gauge vitrectomy. *Ophthalmology*. 2007; 114: 2133-7.
  21. **Hu AY, Bourges JL, Shah SP, Gupta A, Gonzales CR, Oliver SC, Schwartz SD.** Endophthalmitis after pars plana vitrectomy a 20 and 25 - gauge comparison. *Ophthalmology*. 2009; 116: 1360-5.
  22. **Parolini B, Romanelli F, Prigione G, Pertile G.** Incidence of endophthalmitis in a large series of 23 - gauge and 20-gauge transconjunctival pars plana vitrectomy. *Graves Arch Clin Exp Ophthalmology*. 2009; 247: 1711-2.
  23. **Romano MR, Das R, Groenwald C, Stapler T, Marticorena J, Valdeperas X, Wong D, Heimann H.** Primary 23-gauge sutureless vitrectomy for rhegmatogenous retinal detachment. *Indian J Ophthalmol*. 2012; 60: 29-33.